

3T MRI/MRS (MR Spectroscopy) of the PROSTATE: STATE-OF-THE-ART

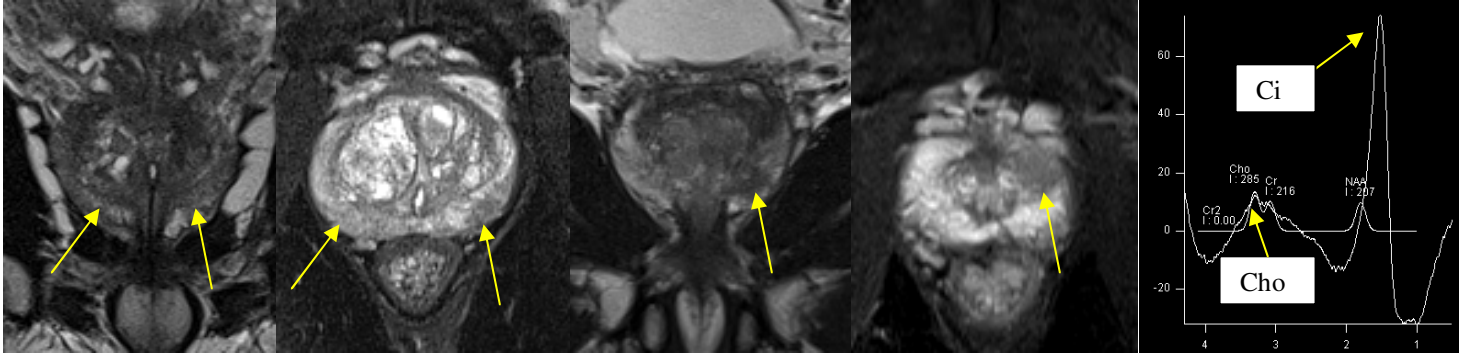


Fig. 1a

Fig 1b

Fig 2a

Fig. 2b

Fig. 3a-b

MRI of the prostate has been around for many years. However, recent advances in MRI such as MR Spectroscopy (MRS) and MR Diffusion imaging have tremendously enhanced its diagnostic and screening capabilities. These new techniques are offered on our new 16-channel 3T MRI in Palmdale. We routinely perform a prostate MRI with MR Diffusion and a Dynamic post-gadolinium scan. MRS is performed as well when requested.

Fig. 1a-b (coronal/axial T2): This patient presented with a "normal" prostate exam but a slightly elevated PSA (around 6.0). MRI showed diffuse low signal changes in the Peripheral Zone (PZ) bilaterally. MR Spectroscopy showed elevated **Choline (Cho)** relative to **Citrate (Ci)** consistent with prostate cancer. Subsequent biopsy confirmed the diagnosis of prostate cancer. No extracapsular extension.

Fig. 2a-b: This patient presented with a nodule. MRI shows a focal low intensity mass in the antero-inferior left PZ (at the apex). Biopsy revealed prostate cancer.

MR SPECTROSCOPY (MRS): MRS uses a special technique to obtain metabolic information (spectra) that can determine the relative concentrations of various metabolites in the cell cytoplasm and the extracellular space, allowing for identification of metabolic differences in prostate tissue (normal tissue, BPH, and cancer). In a normal prostate, the levels of CITRATE are much higher relative to CHOLINE (**Fig. 3a**). In prostate cancer, on the other hand, this relative concentration is reversed and Choline is significantly elevated (**Fig. 3b**).

DISCUSSION: MRI (particularly ultra high-field 3T MRI) in conjunction with MRS, MR Diffusion and post-contrast Dynamic scan are very powerful tools for screening, diagnosis and staging of prostate cancer. Digital Rectal Exam can miss nodules located anteriorly or deep in the center. A portion of prostate cancers can even go undetected with biopsy (sampling error). MRI is a powerful adjunct to help detect these hidden tumors. MRI images can provide a **roadmap** for subsequent **targeted (smart) biopsies**. Most prostate cancers reside in the Peripheral Zone (PZ). MRI/MRS can also detect cancers in the Central Zone (CZ) and Transitional Zone (TZ). **MRS can be used in a variety of conditions including: Prostate CA, Breast CA, Brain Mass (Tumor vs. MS vs. Abscess), just to name a few.**

Ray Hashemi, MD

Ray H. Hashemi, M.D., Ph.D.

Diplomat American Board of Radiology